

International VATS Experiences: Costa Rica

Uluslararası VATS Deneyimleri: Kosta Rika

Dr. Albert Bolaños-Cubillo, Dr. William Guido-Guerrero

Department of Thoracic Surgery, Rafael Ángel Calderón Guardia Hospital, San José, Costa Rica

SUMMARY

Video assisted thoracic surgery (VATS) has been a decisive breakthrough in the development of thoracic surgery. Uniportal VATS has evolved the multiport technique into a less invasive single incision approach, with a wide expansion around the world, including Latin America. In Costa Rica, at Rafael Ángel Calderón Guardia Hospital, multiport VATS began in the late 90's, with a big change to uniportal VATS since 2013, performing even advanced procedures like lobectomies, sleeve resections, non-intubated procedures and subxyphoid surgeries. Thanks to international uniportal VATS training, and two Uniportal VATS masterclass in our center, led by the international recognized expert Dr. Gonzalez-Rivas, our surgical team is applying the technique for almost all procedures with good postoperative results. In this article, the authors describe the experience and learning curve in Costa Rica with this single incision technique.

Keywords: Uniportal VATS, single port VATS, minimally invasive thoracic surgery, lobectomy.

ÖZET

Video yardımcı torasik cerrahi (VATS), torasik cerrahi gelişiminde belirleyici bir atılım olmuştur. Uniportal VATS, multiport tekniğinden daha az invaziv bir tek insizyon yaklaşımı olarak Latin Amerika da dahil olmak üzere dünya çapında yaygınlaşan bir teknik haline gelmiştir. Lobektomiler, sleeve rezeksiyonlar, non-entübe prosedürler ve subksipoid ameliyatları gibi ileri prosedürler Kosta Rika'da, Rafael Ángel Calderón Guardia Hastanesi'nde, multiport VATS olarak, 90'lı yılların sonlarında başlanmış, 2013'ten itibaren büyük bir değişiklik yaparak uniportal VATS'a geçilmiştir. Uluslararası uniportal VATS eğitimi ve merkezimizdeki uluslararası tanınmış uzman Dr. Gonzalez-Rivas liderliğindeki iki Uniportal VATS masterclass sayesinde hemen hemen tüm prosedürler başarılı sonuçlar ile yapılmaktadır. Bu makalede, yazarlar tek insizyon tekniği ile Kosta Rika'daki deneyimi ve öğrenme eğrisini anlatmaktadır.

Anahtar Kelimeler: Uniportal VATS, tek port VATS, minimal invaziv torasik cerrahi, lobektomi.

Yazışma Adresi / Address for Correspondence

Albert Bolaños-Cubillo, MD
Department of Thoracic Surgery, Rafael Ángel Calderón Guardia Hospital, San José, Costa Rica.
e-posta: albertbolanosmd@gmail.com
DOI: 10.5152/gghs.2019.050

Introduction

Video-assisted thoracic surgery (VATS) has become the most important surgical technique for management of different thoracic pathologies. This minimally invasive approach has been changing from using multiple ports to a uniportal approach (Uniportal VATS) with a wide acceptance worldwide⁽¹⁾.

The first reports of using a single port approach were made by Prof. Gaetano Rocco in Italy, with simple procedures like wedge resections, pulmonary biopsies and mediastinal pathologies⁽²⁾. Dr. Gonzalez-Rivas was the first to perform a lobectomy with radical lymphadenectomy by uniportal VATS in 2010⁽³⁾, and since then, different teams around the world have been doing single port minimally invasive procedures⁽⁴⁻⁶⁾, and advancing to more complex and difficult surgeries such as uniportal bronchoplastic sleeve lobectomies, tracheal and carinal resection, and lobectomies with chest wall en bloc resection⁽⁷⁾.

It is now known that single port VATS is less invasive than the multiport technique, results in less postoperative pain with minimal compression of the intercostal nerve, -good cosmetic results, less days in hospital stay, with the same oncological outcome as the open procedure⁽⁸⁾.

The development of this technique has occurred mainly in Asia and Europe, but Central and South America have not been the exception^(9,10). The purpose of this review is to analyze the evolution and the learning curve of Uniportal VATS in Costa Rica.

VATS Experience: The Learning Curve

Costa Rica, as a small country in Central America, started multiport VATS in 1999 at our center. During the first years, at least 25% of the thoracic surgery department's procedures were performed with a thoracoscopic approach at Rafael Ángel Calderón Guardia Hospital, duplicating the number of VATS until 2010. During this period, more than 788 patients were treated with multiport VATS, with single port technique used rarely for diagnostic purposes⁽¹¹⁾.

Since 2013, the uniportal approach was used in almost all thoracoscopic procedures, beginning with lung biopsies, wedge resections for pulmonary nodules, pleural biopsies, mediastinal mass biopsies and drainage of pleural effusions⁽¹²⁾.

The learning curve for VATS instrumentation, dissection skills and the confidence to perform more complex procedures were acquired with phase II and

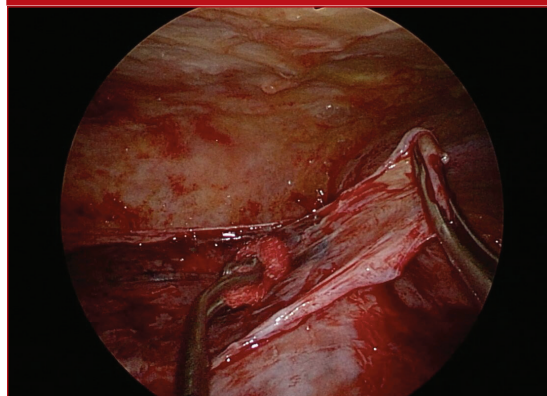
phase III empyema, and with clotted hemothorax (Figure 1). Performing a uniportal VATS drainage and decortication provided us with experience for precision dissection, lung suture skills and extracorporeal knots⁽¹²⁾.

The first Uniportal VATS lobectomy in Costa Rica was performed successfully in 2014 at our center in a non-oncological male patient with bronchiectasis, with a left lower lobe lobectomy⁽¹²⁾.

One of the most important aspects of gaining experience in a new technique is to find a high volume center specialized in the procedure. Attending international meetings and training in wet and dry labs are useful for learning the basics. For the authors, the Uniportal VATS Training Program in Shanghai Pulmonary Hospital was the place to increase the experience and number of cases for major pulmonary resections. At this moment, three surgeons from our team have successfully completed this training in China; the first one in 2014 with a posterior fellowship the same center, the others in 2015 and 2019.

With the idea of optimizing the learning curve and to teach the technique to other surgeons and residents in our country, our center planned the First Masterclass in Uniportal VATS in September 2015, with the help of Dr. Gonzalez-Rivas and invited surgeons from Shanghai Pulmonary Hospital, Dr. Wentao Li and Dr. Yang Yang. The course consisted of two days of lectures and a third day of live surgeries performed by Dr. Gonzalez-Rivas with a single incision approach: a left lower lobectomy, a right upper lobectomy with radical lymphadenectomy, and the first non-intubated uniportal VATS wedge resection of our country⁽¹²⁾.

Figure 1. Uniportal VATS decortication of stage III empyema. VATS: Video-assisted thoracic surgery.



In December 2016, our team carried out the first uniportal VATS bronchial sleeve resection with lung sparing in Costa Rica, on a 27 years male patient with an endobronchial typical carcinoid tumor in the intermediate bronchus, with an excellent postoperative outcome (Figure 2 and 3). The bronchoplastic resections are the most challenging and complex procedures, requiring complete preoperative planning and advanced techniques for managing the camera and dissection, and high level suturing skills to perform an end to end bronchial anastomosis^(7,13).

The desire to improve and to be prepared for more difficult cases, led us to request the collaboration of Dr. Gonzalez-Rivas for the second Masterclass in Uniportal VATS, this time with emphasis in advanced procedures (Figure 4). In August 2018, a two-day course was developed, with morning lectures and live surgeries: a uniportal subxyphoid extended timection, a uniportal VATS timection and a uniportal VATS right main bronchus resection and reconstruction of intermedius and upper bronchus with anastomosis to the carina in a female patient with an early stage endobronchial squamous carcinoma.

Figure 2. Uniportal VATS bronchial sleeve resection with lung sparing, endobronchial typical carcinoid tumor in the intermediate bronchus. VATS: Video-assisted thoracic surgery.

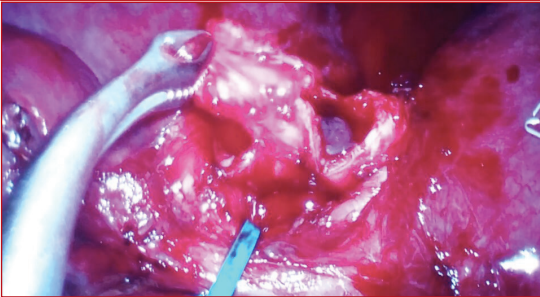


Figure 3. End-to-end bronchial anastomosis during a Uniportal VATS bronchial sleeve resection with lung sparing. VATS: Video-assisted thoracic surgery.

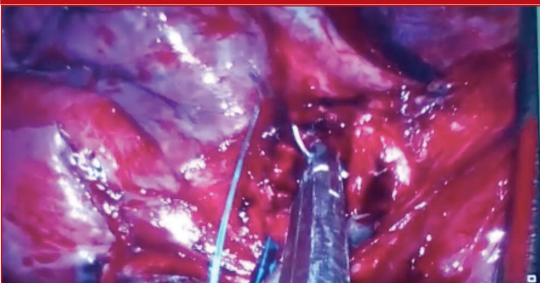
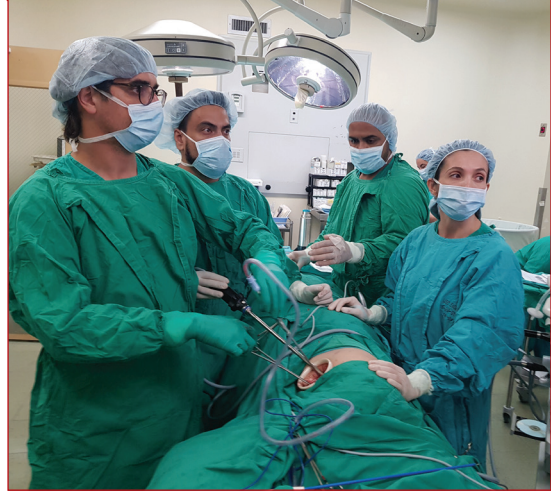

Figure 4. Live surgery performed by Dr. Gonzalez-Rivas during second uniportal VATS masterclass in advanced procedures at Rafael Ángel Calderón Guardia Hospital, Costa Rica. VATS: Video-assisted thoracic surgery.



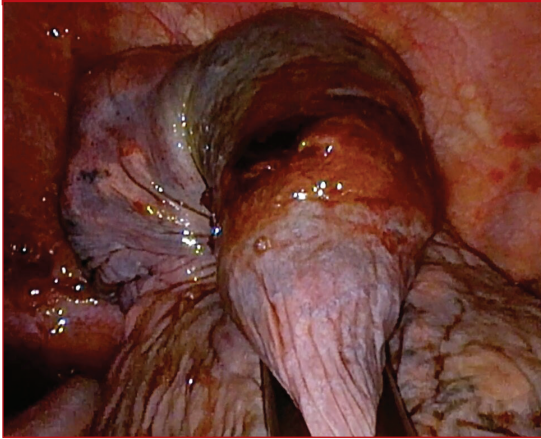
Since 2013, our center has performed more than 400 uniportal thoracoscopic procedures, with at least 100 uniportal drainage and decortication for empyema and clotted haemothorax, including phase III empyema, more than 50 uniportal lobectomies and 200 cases of single port lung biopsies, wedge resections, mediastinal mass biopsies and resections. For more complex procedures, our hospital carried out 5 subxyphoid wedge resections and lung biopsies, 1 subxyphoid timection, 2 uniportal vats wedge resection with non-intubated patient, 1 uniportal VATS bronchial sleeve with lung sparing and 1 single port bronchial resection with main carina reconstruction.

In the acute trauma patient, our team has performed uniportal VATS exploration for patients with thoracic gunfire wounds for persistent air leaks and for acute traumatic hemothorax in a secure way with good postoperative results (Figure 5).

Problems at Resections and Challenges

To perform advanced procedures with a good surgical outcome, it is necessary to have vast experience with the uniportal technique. With this context, a high number of cases are necessary to develop the skills, confidence and security to operate the patient, allowing a wide learning curve for the procedure⁽¹²⁾. In a low volume institution, almost every case must be performed with this technique to increase the experience of its surgeons for more difficult cases.

Figure 5. Left Uniportal VATS wedge resection of segment 1, due to gunshot wound with persistent air leak and hemothorax. VATS: Video-assisted thoracic surgery.



There were a lot of problems when the authors implemented this new surgical technique in a public health hospital: a change in the optimal anesthetic setup, selection and number of patient for this minimally invasive approach, availability of thoracoscope and specialized uniportal VATS instruments, difficulties for managing the instruments and camera in a single incision in the first years of the program, and the handle of intraoperative complications.

Even a simple procedure like a wedge resection can become a challenging case, even more with a major lung resection. The presence of previous surgery or pleurodesis, a frozen pulmonary hilum with calcified lymph nodes, pleural adhesions secondary to tuberculosis or inflammatory diseases, absence of interlobar fissures, large tumors, or patients with medical conditions that can lead to major bleeding during the transoperative period, like anticoagulation therapy or extra corporeal membrane oxygenation therapy⁽¹⁴⁾, were some of the difficult situations to manage during the learning curve.

The surgeon must have the ability to recognize some dangerous situations and realize when to continue with a minimally invasive procedure or switch to open surgery. For the safety of the patient, a conversion to open surgery is not a failure of the procedure, especially if the surgeon doesn't have experience to handle a big bleeding with a uniportal approach^(15,16). With more cases, the conversion rate can be maintained in low values with improve in the capability to resolve these complications with a minimally invasive technique⁽¹⁷⁾.

Tips and Tricks

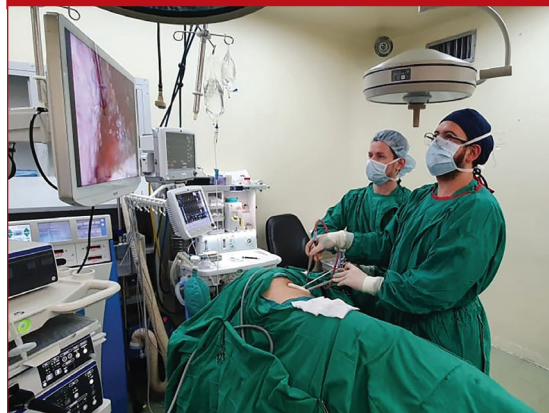In our own learning curve, our team has used some tips and tricks to improve the overall experience with the technique. During the first years doing uniportal surgery, a 10mm lens was always used, but nowadays we switched to the 5mm lens for every procedure. It maximizes the space in the incision without compromising the quality of the image, which is as good as the 10 mm lens in the majority of versions with recent technology.

The use of a wound retractor prevents the lens from getting dirtier and makes for an easier introduction of the instruments⁽¹⁸⁾. In the first cases, the authors used a suture stitch in the muscle and subcutaneous tissue to maintain open the space.

Handling the camera in uniportal VATS requires skills and expertise^(18,19). In low volume centers, it is better if the learning curve is shared between the surgeon and assistant, as it will allow them to grow together in experience with each procedure, enabling them to engage in more complex cases sooner than if the main surgeon performs the procedure with a different assistant every time (Figure 6).

Choosing the uniportal approach for every procedure that is going to be performed in a minimally invasive manner, instead of only selecting certain type of cases, will allow the surgeon to familiarize with the particularities of the technique faster. In our institution, stage II and III empyema were a great teaching, since performing a complete decortication and drainage of such cases gave us experience in instrumentation and dissection to be able to perform more complex procedures.

Figure 6. Surgical team during right uniportal VATS decortication of a stage III empyema. VATS: Video-assisted thoracic surgery.



The beginning of the surgery is very important: the incision is a 2-4 cm single muscle-sparing one, so the serratus muscle is opened longitudinally through its fibers, the intercostal muscle is always cut in the upper part of the lower rib, and enlarging the inner part of the incision should be avoided in order to prevent postoperative subcutaneous emphysema^(19,20).

The dissection of the vascular structures during a uniportal lobectomy is one of the most important steps of the procedure. It is very useful to clean the vein and the artery of the surrounded soft tissue and to dissect as distally and proximally of the vessel as possible, to facilitate the insertion of the stapler (Figure 7).

Sometimes, the angles are difficult; a stapler with a reticulating head and a curved tip in the thin anvil jaw makes this step easier (Figure 8). Using a tape can be helpful in difficult situations, because it can pull the vessel and widen the space⁽¹⁹⁻²¹⁾.

The lymph nodes dissection is a relevant part in uniportal VATS oncological lung major resection. A good exposure, proper traction of the lung, bimanual instrumentation and the use of energy devices are very useful for a complete mediastinal dissection⁽²²⁾. Our team prefers to use a curved suction device to pull the lymph nodes and an energy device, like an ultrasonic scalpel, to maintain the hemostasis. The use of a sponge stick or a VATS curved ring forceps can help manage the lymph nodes in an easier way.

Prophylactic conversion is always better than an emergency conversion. Clinical judgment of the surgeon must be always present to avoid forcing steps in the surgery in which intraoperative complications may arise. Choosing to convert before this happens is

Figure 7. Dissection of the right lower lobe artery in the fissure during Uniportal VATS right lower lobectomy. VATS: Video-assisted thoracic surgery.

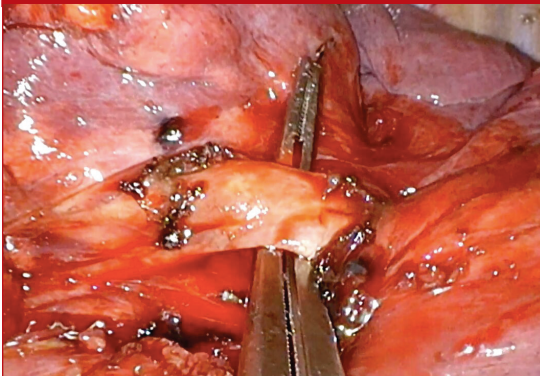
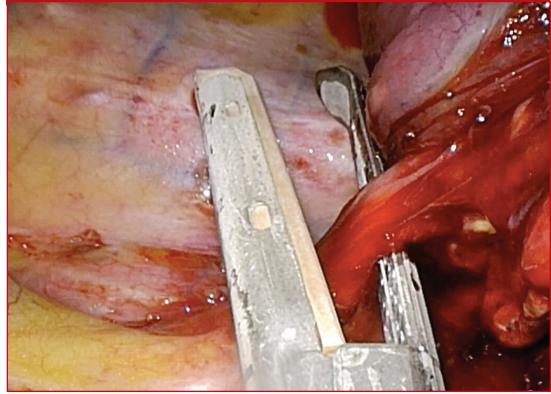


Figure 8. Division of right inferior pulmonary vein with a curved tip stapler during Uniportal VATS right lower lobectomy. VATS: Video-assisted thoracic surgery.



wise and should never be regarded as a failure, but as a prevention of a failure instead⁽¹⁷⁾.

The authors usually insert only one 28 Fr chest tube in the upper part of the same incision, towards the posterior and apical aspect of the pleural space; however, for wedge resections or pleural biopsies, a small gauge pleural catheter (10 Fr) can sometimes be used (Figure 9 and 10) or pleural drainage can be avoided altogether, since it is very important to accompany the uniportal approach with a fast track protocol to actually take advantage of the benefits of the technique^(19,23).

Our team closes the wound in layers with absorbable sutures; this prevents subcutaneous emphysema and avoids retraction of the skin⁽¹⁹⁾. At the end, the chest tube is fixed to the skin with a Halsted stitch with a non-absorbable monofilament suture, to facilitate the posterior safe extraction and closure of the defect left by the pleural drainage.

Figure 9. Single chest tube placed in the posterior part of incision after uniportal right lower lobectomy. VATS: Video-assisted thoracic surgery.

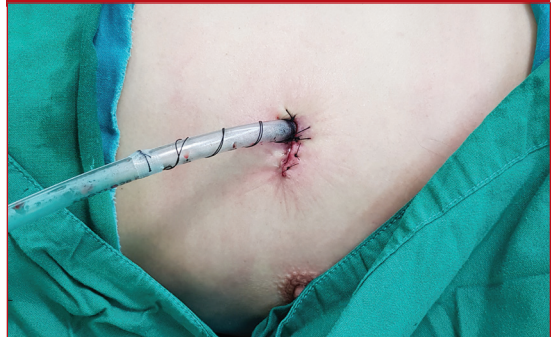
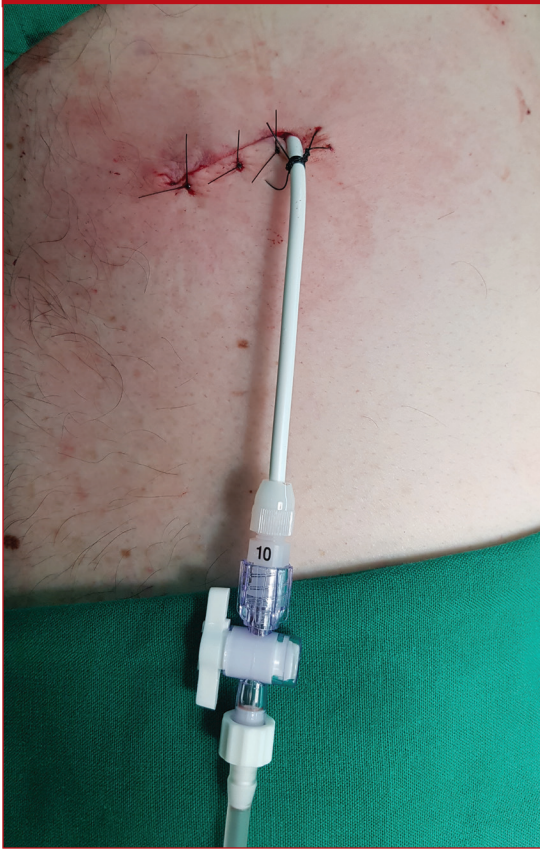
Figure 10. Single low-caliber pleural drain placed through the incision after a uniportal wedge resection. VATS: Video-assisted thoracic surgery.



To optimize pain control, our group used an intercostal block with long-acting local anesthetics under direct vision in at least three intercostal spaces at the level of the incision. Now, with the help of the anesthesiology service, at the end of almost all uniportal procedures, an ultrasound-guided paravertebral block or an erector spinae plane block is performed. These techniques provide a better analgesia than thoracic epidural catheter, with less side effects, morbidity and reduced use of opioids^(24,25).

Conclusions

Uniportal VATS is a feasible and safe technique in the hands of thoracic surgeons, with a fast learning curve; and the experience acquired with simple procedures, allows expert surgeons to perform more complex cases, such as lobectomies, segmentectomies and bronchoplastic resections.

The support of the entire thoracic surgery department was essential with the first cases and the guidance and mentoring of expert surgeons and inter-

national uniportal VATS courses led our team to gain confidence and to currently apply this technique as the standard approach for all VATS cases, improving our surgical time, our postoperative results, facilitating the procedure, and giving the patients of Costa Rica the best treatment option as done in the rest of the world.

The experience obtained in our center can open the doors for developing training programs in Costa Rica, to widespread and adopt this less invasive technique for thoracic surgeons and residents from the region and demonstrate the applicability of uniportal VATS during simple and more advanced procedures.

REFERENCES

1. Mineo TC, Ambrogi V. A glance at the history of uniportal video-assisted thoracic surgery. *J Vis Surg* 2017; 3:157-169.
2. Rocco G, Martin-Ucar A, Passera E. Uniportal VATS wedge pulmonary resections. *Ann Thorac Surg* 2004; 77: 726-8.
3. Gonzalez D, Paradela M, Garcia J, dela Torre M. Single-port video-assisted thoracoscopic lobectomy. *Interact Cardiovasc Thorac Surg* 2011; 12(3): 514-515.
4. Wang, H., Zhou, X., Xie, D., Jiang, S., Ding, H., Gonzalez, D., & Jiang, G. Uniportal video-assisted thoracic surgery-the experiences of Shanghai Pulmonary Hospital. *J Vis Surg* 2016; 2:56-59.
5. Ismail M, Helmig M, Swierzy M, Neudecker J, Badakhshi H, Gonzalez-Rivas D, Rückert JC. Uniportal VATS: the first German experience. *J Thorac Dis* 2014; 6(6):S650-S655.
6. Akar FA, Gonzalez-Rivas D, Ismail M, Deeb M, Reichenshtein Y, Hadas-Halpern I, Tauber R, Fink D. Uniportal video-assisted thoracic surgery: the Middle East experience. *J Thorac Dis* 2017; 9(4):871-877.
7. Guido-Guerrero W, Bolaños-Cubillo A, González-Rivas D. Single-port video-assisted thoracic surgery (VATS)-advanced procedures & update. *J Thorac Dis* 2018; 10: 1652-61.
8. Harris CG, James RS, Tian DH, et al. Systematic review and meta-analysis of uniportal versus multiportal video-assisted thoracoscopic lobectomy for lung cancer. *Ann Cardiothorac Surg* 2016; 5:76-84.
9. Bondulich G, Gonzalez Rivas D. Uniportal video-assisted thoracoscopic surgery, argentinian experience. *J Vis Surg* 2017; 3: 60-3.
10. Clavero JM. Single port training in Latin-America-first uniportal video-assisted thoracoscopic surgery masterclass in Santiago, Chile. *J Vis Surg* 2016; 2: 140-143.
11. Mainieri-Hidalgo JA. Experiencia de 10 años con cirugía mínimamente invasiva del tórax, en el Hospital Dr. Rafael Ángel Calderón Guardia. *Acta Med Costarric* 2010; 52: 26-9.
12. Guido Guerrero W, Gonzalez-Rivas D, Yang Y, Li W. The evolution of uniportal video assisted thoracic surgery in Costa Rica. *J Vis Surg* 2016; 2: 1-4.

13. Gonzalez-Rivas D, Yang Y, Sekhniaidze D, Stupnik T, Fernandez R, Lei J, Zhu Y, Jiang G. Uniportal video-assisted thoracoscopic bronchoplastic and carinal sleeve procedures. *J Thorac Dis* 2016; 8: 210-22.
14. Sihoe AD. Are There Contraindications for Uniportal Video-Assisted Thoracic Surgery? *Thorac Surg Clin* 2017; 27: 373-80.
15. Gonzalez-Rivas D, Stupnik T, Fernandez R, de la Torre M, Velasco C, Yang Y, Lee W, Jiang G. Intraoperative bleeding control by uniportal video-assisted thoracoscopic surgery. *Eur J Cardiothorac Surg* 2015; 49(1): i17-i24.
16. Scarci M, Gonzalez-Rivas D, Schmidt J, Bedetti B. Management of Intraoperative Difficulties During Uniportal Video-Assisted Thoracoscopic Surgery. *Thorac Surg Clin* 2017; 27: 339-46.
17. Baranowski R, Waller DA. How high is your conversion rate? as high as necessary. *Ann Transl Med* 2019; 7(1): 23-25.
18. Ismail M. Room Set Up and Instrumentation. In: Gonzalez-Rivas D, Ng C, Rocco G, D'Amico T (eds). *Atlas of Uniportal Video Assisted Thoracic Surgery*. Springer: Singapore 2019: 23-7.
19. Gonzalez-Rivas D, Sihoe AD. Important technical details during uniportal video-assisted thoracoscopic major resections. *Thorac Surg Clin* 2017; 27(4): 357-372.
20. Ismail M, Swierzy M, Nachira D, Rückert JC, Gonzalez-Rivas D. Uniportal video-assisted thoracic surgery for major lung resections: Pitfalls, tips and tricks. *J Thorac Dis* 2017; 9: 885-97.
21. Costa EF, Roel MD, de la Morena MP, Gonzalez-Rivas D, Fernandez-Prado R, De La Torre M. Technique of uniportal VATS major pulmonary resections. *J Thorac Dis* 2014; 6: 660-4.
22. Roel MD, Costa EM, González-Rivas D, Fernández LM, Prado RF, de la Torre M. Uniportal video-assisted thoracoscopic lymph node dissection. *J Thorac Dis* 2014; 6(6):S665.
23. Batchelor TJ, Rasburn NJ, Abdelnour-Berchtold E, Brunelli A, Cerfolio RJ, Gonzalez M, et al. Guidelines for enhanced recovery after lung surgery: recommendations of the Enhanced Recovery After Surgery (ERAS®) Society and the European Society of Thoracic Surgeons (ESTS). *Eur J Cardiothorac Surg* 2018; 55: 91-115.
24. Adhikary SD, Pruett A, Forero M, Thiruvankatarajan V. Erector spinae plane block as an alternative to epidural analgesia for post-operative analgesia following video-assisted thoracoscopic surgery: a case study and a literature review on the spread of local anaesthetic in the erector spinae plane. *Indian J Anaesth*. 2018; 62: 75-8.
25. Hu Z, Liu D, Wang ZZ, Wang B, Dai T. The efficacy of thoracic paravertebral block for thoracoscopic surgery: A meta-analysis of randomized controlled trials. *Medicine* 2018; 97: 1-6.